

## POSTCHOLECYSTECTOMY SYNDROME, OR CONDITION AFTER CHOLECYSTECTOMY (GALLBLADDER REMOVAL)

The [laparoscopic cholecystectomy](#) is considered the “gold standard” in chronic calculous cholecystitis treatment. After the gallbladder removal the physiology of gallbladder bile formation is changed.

Absence of the gallbladder leads to development of functional biliary hypertension and dilatation of common bile duct and the common hepatic duct (1-8). The dilatation of right and left hepatic ducts may be formed within 3-5 years after cholecystectomy (1-8). Functional hypertension in the common bile duct leads to development of functional hypertension in Wirsung's pancreatic duct accompanied by chronic pancreatitis symptoms (1-8).

During this period in some patients this is accompanied by [chronic pancreatitis progression, dysfunction of the sphincter of Oddi and duodeno-gastral reflux](#) (1-17). Duodeno-gastral reflux causes the development of atrophic ([bile-acid-dependent](#)) antral gastritis (1-11). After cholecystectomy 40% to 60% of patients suffer from dyspeptic disorders, 5% to 40% from pains of different localizations (1-17). Up to 70% of patients show symptoms of chronic “bland” intrahepatic cholestasis, chronic cholestatic hepatitis and compensatory bile-acid-dependent apoptosis of hepatocytes (11-15). In some of cholecystectomized patients with high concentration of hydrophobic hepatotoxic co-carcinogenic deoxycholic bile acid in serum and/or feces high risk of the colon cancer is found.

Therefore, depending on [dysfunction \(hyper tonus\) or relaxation \(hypo tonus\) of the sphincter of Oddi](#), pathology in hepato-biliary-pancreato-duodenal-gastral zone will form after cholecystectomy.

Postcholecystectomy syndrome is a dysfunction of the sphincter of Oddi, caused by noncalculous obstructive disorder, which decrease bile passage and pancreatic juice outflow into the duodenum (1-2).

### DIAGNOSTIC CRITERIA OF THE SPHINCTER ODDI DYSFUNCTION

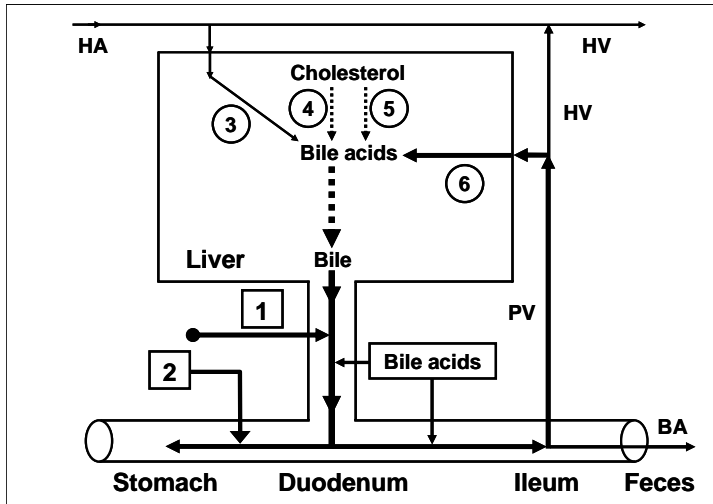
1. Complex of functional disorders continuing more than 3 months, among which the main clinic symptoms are recurrent severe and moderate pains lasting for more than 20 minutes, accompanied by nausea and/or vomiting and located in
  - a. epigastrium or right hypochondrium with irradiation in the back and in the right scapular region ([biliary type](#))
  - b. left hypochondrium with irradiation in the back, abating when bending forward ([pancreatic type](#))
  - c. girdle pain ([combined type](#))
  - d. unstable stool with often cases of constipation or diarrhea
  - e. dyspeptic syndromePain may be accompanied by the following symptoms:
  - pain occurs after meal
  - pain occurs at night
2. According to ultrasound examination data, dilatation of the common bile duct is up to 4-10 mm.
3. [The sphincter of Oddi incompetence](#) is accompanied by increased hepatic bile passage into the duodenum and formation of duodeno-gastral reflux.

### CAUSES OF THE BILIARY PAIN AND CHRONIC INFLAMMATION IN THE BILIARY TRACT AND THE SPHINCTER OF ODDI

1. Pathology of the smooth muscle cells and epithelial cells in the biliary tract ([high degree of COX-2 expression in the smooth muscle cells and epithelial cells of the bile ducts and the sphincter of Oddi](#)).
2. Hypersecretion of glycoprotein biliary mucin into bile ducts lumen ([high degree of COX-2 expression in the epithelial cells of the bile ducts](#)).
3. Increased basal common bile duct resistance ([high degree of COX-2 expression in the smooth muscle cells of the sphincter of Oddi](#)).

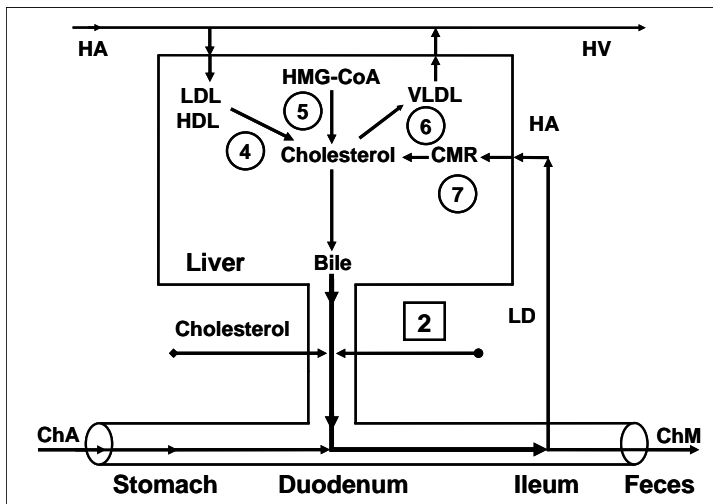
### MECHANISM OF DEVELOPMENT OF PATHOLOGIC DISORDERS

Absence of the gallbladder leads to surplus passage of hepatic bile only into the duodenum and increases frequency of [gallbladder-independent enterohepatic circulation of bile acids](#). There is only [gallbladder-independent enterohepatic circulation of bile acids](#) in patients after cholecystectomy (fig. 33).



**Fig. 33.** Enterohepatic circulation of bile acids in patients after cholecystectomy. **1** = gallbladder-independent enterohepatic circulation of bile acids; **2** = duodeno-gastral reflux; **4** = synthesis of cholic acid: cholesterol-7 $\alpha$ -hydroxylase; **5** = synthesis of chenodeoxycholic acid: cholesterol-27-hydroxylase; **6** = bile acids entering the liver through the portal vein. **BA** = bile acids; **HA** = hepatic artery; **HV** = hepatic vein; **PV** = portal vein.

Absence of the gallbladder after cholecystectomy causes the increase in passage of hepatic bile into the duodenum and the [gallbladder-independent enterohepatic circulation of biliary cholesterol and bilirubin](#) (fig. 34).

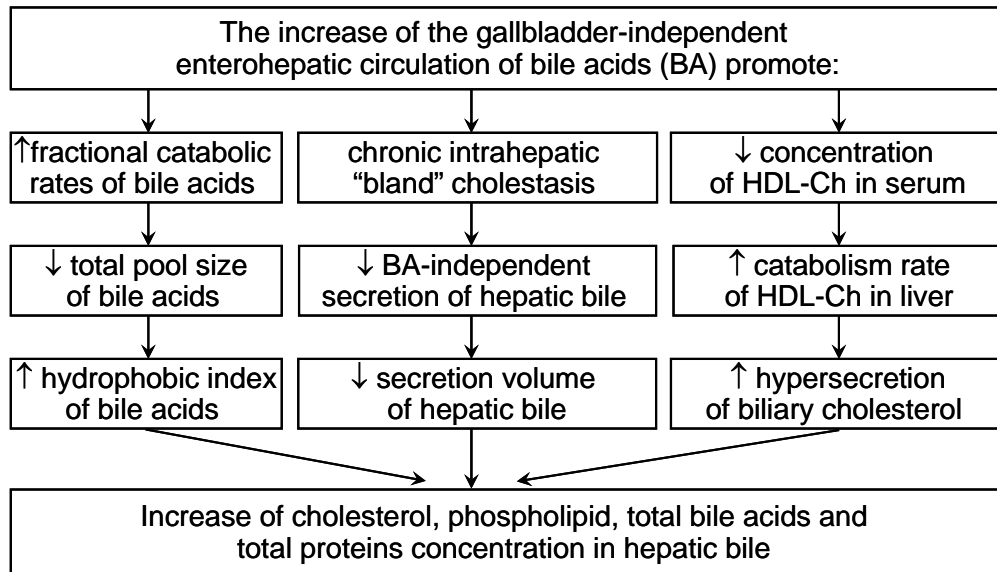


**Fig. 34.** Exchange of cholesterol in patients in patients after cholecystectomy. **2** = gallbladder-independent output of biliary cholesterol; **4** = hydrolysis of cholesterol esters entered the hepatocytes with HDL and LDL; **5** = synthesis of cholesterol; **6** = synthesis of cholesterol esters for VLDL; **7** = hydrolysis of cholesterol esters entered the hepatocytes with CMR. **ChA** = cholesterol anhydrous; **ChM** = cholesterol monohydrate; **HA** = hepatic artery; **HV** = hepatic vein; **PV** = portal vein; **LD** = lymphatic duct.

Increase in [gallbladder-independent enterohepatic circulation of bile acids](#) causes increase in concentration of bile acids in the hepatocytes and decrease in the accumulation function and excretion function of the liver (i.e. formation of chronic "bland" intrahepatic cholestasis) (fig. 33).

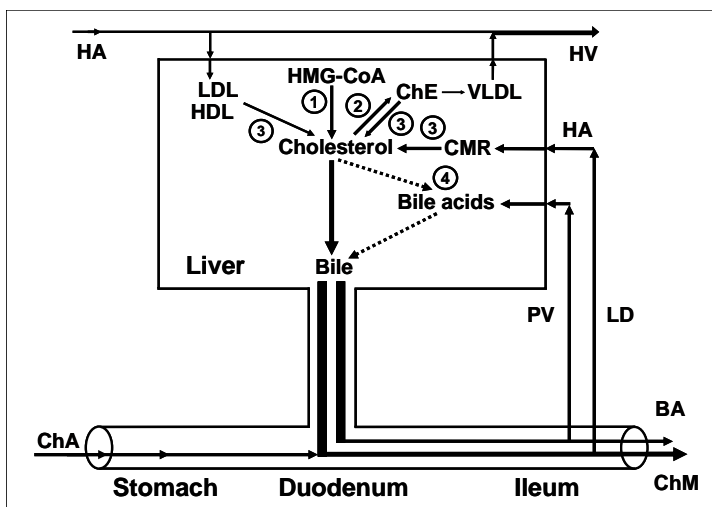
Increase in [the gallbladder-independent enterohepatic circulation of biliary cholesterol](#) helps in increase of absorption of biliary cholesterol in the small intestine, the biliary cholesterol entering hepatocytes, and hypersecretion into hepatic bile (fig. 34).

This factor contributes to the formation of the "lithogenic" hepatic bile and predisposes to choledocholithiasis (formation of gallstones in bile ducts) (fig. 35).



**Fig. 35.** Mechanism of lithogenic hepatic bile formation in patients after cholecystectomy.

Increase in the gallbladder-dependent output of biliary cholesterol and in the concentration of total bile acids in duodenal bile causes the precipitation of cholesterol monohydrate crystals in the duodenum lumen in postcholecystectomic patients (fig. 36).

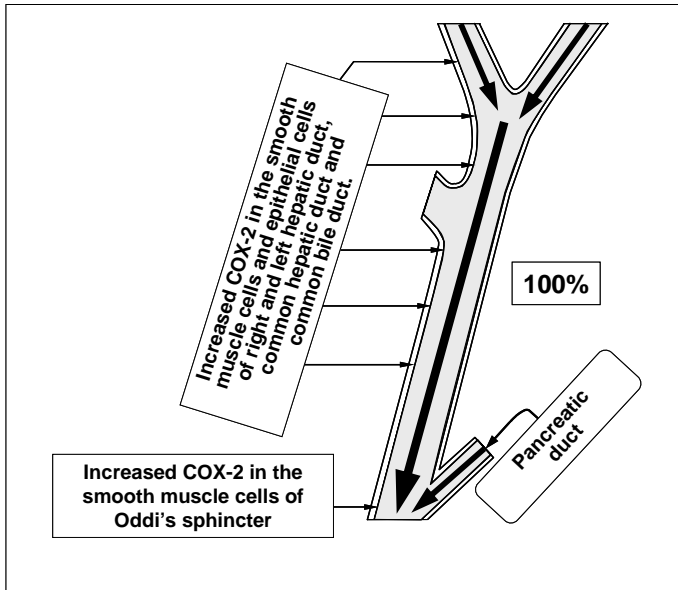


**Fig. 36.** Exchange of cholesterol and bile acids in patients after cholecystectomy.

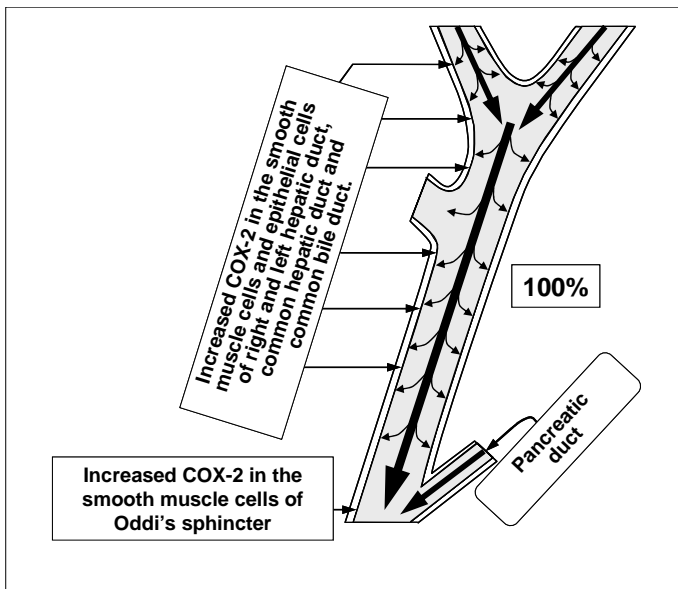
1 = synthesis of cholesterol;  
 2 = synthesis of cholesterol esters for VLDL;  
 3 = hydrolysis of cholesterol esters entered the hepatocytes with HDL and LDL, and hydrolysis of cholesterol esters entered the hepatocytes with CMR;  
 4 = synthesis of bile acids.  
 ChE = cholesterol esters;  
 ChA = cholesterol anhydrous;  
 ChM = cholesterol monohydrate;  
 BA = bile acids; HA = hepatic artery;  
 HV = hepatic vein; PV = portal vein;  
 LD = lymphatic duct.

Due to the sphincter of Oddi incompetence surplus hepatic bile passage into the duodenum causes formation of duodeno-gastral reflux and development of chronic atrophic (bile-acid-dependent) antral gastritis, often accompanied by intestinal metaplasia, and gastroduodenitis (fig. 33, fig. 37).

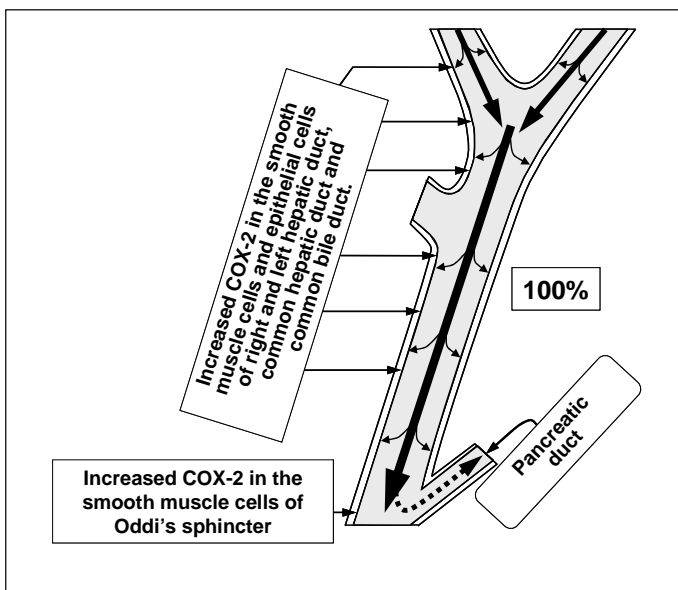
Due to dysfunction of the sphincter of Oddi (high degree of COX-2 expression in the smooth muscle and epithelial cells of the sphincter of Oddi), hindered passage of hepatic bile into the duodenum causes development of the functional biliary hypertension, dilating of the common hepatic duct and common bile duct, development of the biliary pain in epigastrium or right hypochondrium (high degree of COX-2 expression in the smooth muscle and epithelial cells of the biliary tract), and chronic "bland" intrahepatic cholestasis and/or reactive hepatitis (fig. 38).



**Fig. 37.** “Passive” passage of hepatic bile into the duodenum in patients after cholecystectomy at the incompetence of Oddi's sphincter.

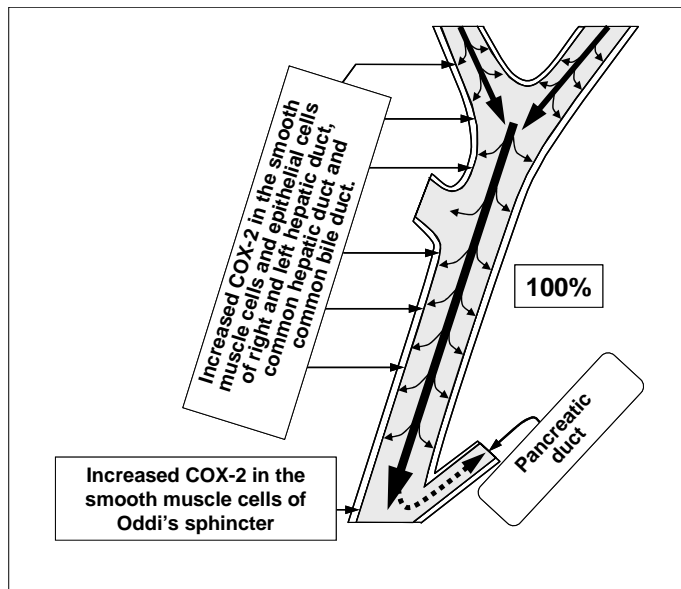


**Fig. 38.** “Passive” passage of hepatic bile into the duodenum in patients after cholecystectomy with Oddi's sphincter dysfunction (biliary type).



**Fig. 39.** “Passive” passage of hepatic bile into the duodenum in patients after cholecystectomy with Oddi's sphincter dysfunction (pancreatic type).

In some postcholecystectomic patients who have the sphincter of Oddi dysfunction ([high degree of COX-2 expression in the smooth muscle and epithelial cells of the sphincter of Oddi](#)), hindered passage of hepatic bile into the duodenum causes development of the functional biliary hypertension in the common bile duct, the functional hypertension in the Wirsung's duct, the pain syndrome in the left hypochondrium, and the symptoms of chronic biliary pancreatitis ([pancreatic type](#)) (fig. 39).



**Fig. 40.** “Passive” passage of hepatic bile into the duodenum in patients after cholecystectomy with Oddi's sphincter dysfunction (combined type).

Due to dysfunction of the sphincter of Oddi ([high degree of COX-2 expression in the smooth muscle and epithelial cells of the sphincter of Oddi](#)), hindered passage of hepatic bile into the duodenum causes development of the functional biliary hypertension dilating of the common hepatic duct and common bile duct, development of the biliary pain in epigastrium or right hypochondrium ([high degree of COX-2 expression in the smooth muscle and epithelial cells of the biliary tract](#)), chronic “bland” intrahepatic cholestasis and/or reactive hepatitis, the functional hypertension in the Wirsung's duct, the pain syndrome in the left hypochondrium, and the symptoms of chronic biliary pancreatitis ([combined type](#)) (fig. 40).

#### **PATHOGENETIC TREATMENT OF PATIENTS AFTER CHOLECYSTECTOMY**

Accordingly, treatment for patients after cholecystectomy ([Postcholecystectomy syndrome is a dysfunction or incompetence of the sphincter of Oddi](#)) (with biliary pain), aiming for the prophylactics of choledocholithiasis, duodeno-gastral reflux, antral atrophic (bile-acid-dependent) gastritis and chronic biliary pancreatitis includes:

1. [Celebrex \(Celecoxib\)](#) – 100 mg, 2 times a day after meal for 5-7 days, after which
2. [Ursofalk or Ursosan \(ursodeoxycholic acid\)](#) – 750 mg, once a day in the evening for 2 month.

[Celebrex \(Celecoxib\)](#) is a selective inhibitor of COX-2. Inhibiting COX-2 activity in the smooth muscle cells of the biliary tract and the sphincter of Oddi it brings relief of the biliary pain within 3-5 days, restoration of the [passage of the hepatic bile into the duodenum](#).

[Celebrex \(Celecoxib\)](#) is a selective inhibitor of COX-2, inhibiting COX-2 activity in the epithelial cells of the biliary tract mucosa causes decrease in secretion of glycoprotein mucin into the biliary tract lumen, concentration of the glycoprotein biliary mucin in the hepatic bile and viscosity of hepatic bile, which prevents formation of biliary sludge and gallstones in the common hepatic duct and common bile duct. Low COX-2 activity in the epithelial cells and the smooth muscle cells of the biliary tract helps in lowering the risk of choledocholithiasis development.

[Ursofalk or Ursosan \(ursodeoxycholic acid\)](#), is a hydrophilic hepatoprotective bile acid. It helps in dissolving the cholesterol monohydrate crystals in the biliary tract, decrease in lithogenicity

of hepatic bile, disappearance of the chronic “bland” intrahepatic cholestasis (i.e. results in the restoration of the accumulation and excretion functions of liver), and in some patients helps in dissolving the biliary sludge in the biliary tract.

**Ursofalk or Ursosan (ursodeoxycholic acid)**, is a hydrophilic hepatoprotective bile acid, decreasing aggressive properties of bile, prevents development of **duodeno-gastral reflux** and **chronic atrophic (bile-acid-dependent) antral gastritis**, often accompanied by intestinal metaplasia, and gastroduodenitis.

**Celebrex (Celecoxib) and Ursofalk or Ursosan (ursodeoxycholic acid)**, pathogenetically blocking main mechanisms of gallstone formation, help in prophylactics of gallstone formation in the biliary tract, and lower the risk of development of choledocholithiasis and chronic biliary pancreatitis.

**Expected effectiveness** is 90-95%.

**Remission period** is 18-24 months.

**Attention!!!** Information for patients:

Before using this scheme of treatment please check the contraindications (below) and side effects of using pharmacological preparations of **Celebrex (Celecoxib)** and **Ursofalk or Ursosan (ursodeoxycholic acid)**, and obtain your doctor's permission.

Contraindications for **Celebrex (Celecoxib)**:

- allergic reactions (nettle-rash, bronchial spasm) to acetylsalicylic acid or other NSAIDs (in anamnesis);
- 3<sup>rd</sup> trimester of pregnancy;
- high sensitivity to sulphonamides;
- high sensitivity to any component of the preparation.

Contraindications for **Ursofalk or Ursosan (ursodeoxycholic acid)**:

- high sensitivity to the preparation;
- acute inflammatory diseases of the gallbladder and the bile ducts;
- ulcerative colitis;
- Crone's disease.

This web page does not bear any legal responsibility for usage of the treatment schemes, given here, without consulting your doctor.

#### REFERENCES:

1. Extrahepatic biliary system diseases: the gallbladder dysfunction and states after cholecystectomy. International Bulletin: gastroenterology. 2001; 6: 1-4.
2. Ilchenko A.A. Postcholecystectomy syndrome: clinical aspects of problem. Consilium Medicum. Gastroenterology. 2006; 2.
3. Komarov F.I., Galkin V.A., Ivanov A.I., Maksimov V.A. Associated diseases of organs of duodenocholedochopancreatic zone. M.: Medicine, 1983: 1-256.
4. Zubovski G.A., ed. Radio and ultrasonic diagnosis of biliary tract diseases. Moscow: Medicine, 1987: 1-240.
5. Barthet M., Affriat C., Bernard J.P. et al. Is biliary lithiasis associated with pancreatographic changes? Gut. 1995; 36(5): 761-765.
6. Barthet M., Spinoza S., Affriat C. et al. Influence of age and biliary lithiasis on the diameter of the common bile duct. Gastroenterol. clin. Biol. 1995; 19: 156-160.
7. Potter G.D. Bile acid diarrhea. Dig. Dis. Sci. 1998; 16: 118-124.
8. Popovic O., Mivolic V., Kostic K. et al. Bile acid-mediated postcholecystectomy diarrhea // Gastroenterol. Inter. 1988; 1: Abstr. 790.
9. Portincasa P., van de Meeberg P., van Erpecum K.J. et al. An update on the pathogenesis and treatment of cholesterol gallstones. Scand. J. Gastroenterol. 1997; 223: 60-69.

10. Portincasa P., di Ciaula A., Palmieri V. et al. Impaired gallbladder and gastric motility and pathological gastroesophageal reflux in gallstone patients. *Europ. J. clin. Invest.* 1997; 27: 653-661.
11. Fort J.M., Azpiroz F., Casellas F. et al. Bowel habit after cholecystectomy: physiological changes and clinical implications. *Gastroenterology.* 1996; 111: 617-622.
12. Isogai M., Yamaguchi A., Hori A., Nakano S. Hepatic histopathological changes in biliary pancreatitis. *Amer. J. Gastroenterol.* 1995; 90(3): 449-454.
13. Mulvihill S.J. Surgical management of gallstone disease and postoperative complications. In: M. Feldman, B.F. Scharschmidt, M.H. Sleisenger, eds. *Sleisenger and Fordtran's Gastrointestinal and Liver Disease: Pathophysiology, Diagnosis, Management.* 6<sup>th</sup> ed. Philadelphia: WB Saunders Company, 1998: 973-984.
14. Honda A., Yoshida T., Tanaka N., Matsuzaki Y., He B., Shoda J., Osuga T. Increased bile acid concentration in liver tissue with cholesterol gallstone disease. *J Gastroenterol* 1995; 30(1): 61-66.
15. Geraghty J.M., Goldin R.D. Liver changes associated with cholecystitis. *J Clin Pathol* 1994; 47(5): 457-60.
16. Carey M.C., Duane W.C. Enterohepatic circulation. In: Arias I.M., Boyer J.L., Fausto N., Jakobson W.B., Schachter D.A., Shafritz D.A., eds. *The Liver, Biology and Pathobiology.* 3<sup>rd</sup> ed. New York: Raven Press, 1994: 719-767.
17. Hofmann A.F. Bile secretion and the enterohepatic circulation of bile acids. In: Feldman M., Scharschmidt B.F., Sleisenger M.H., eds. *Sleisenger and Fordtran's Gastrointestinal and Liver Disease: Pathophysiology, Diagnosis, Management.* 6<sup>th</sup> ed. Philadelphia: WB Saunders Company, 1998: 937-948.