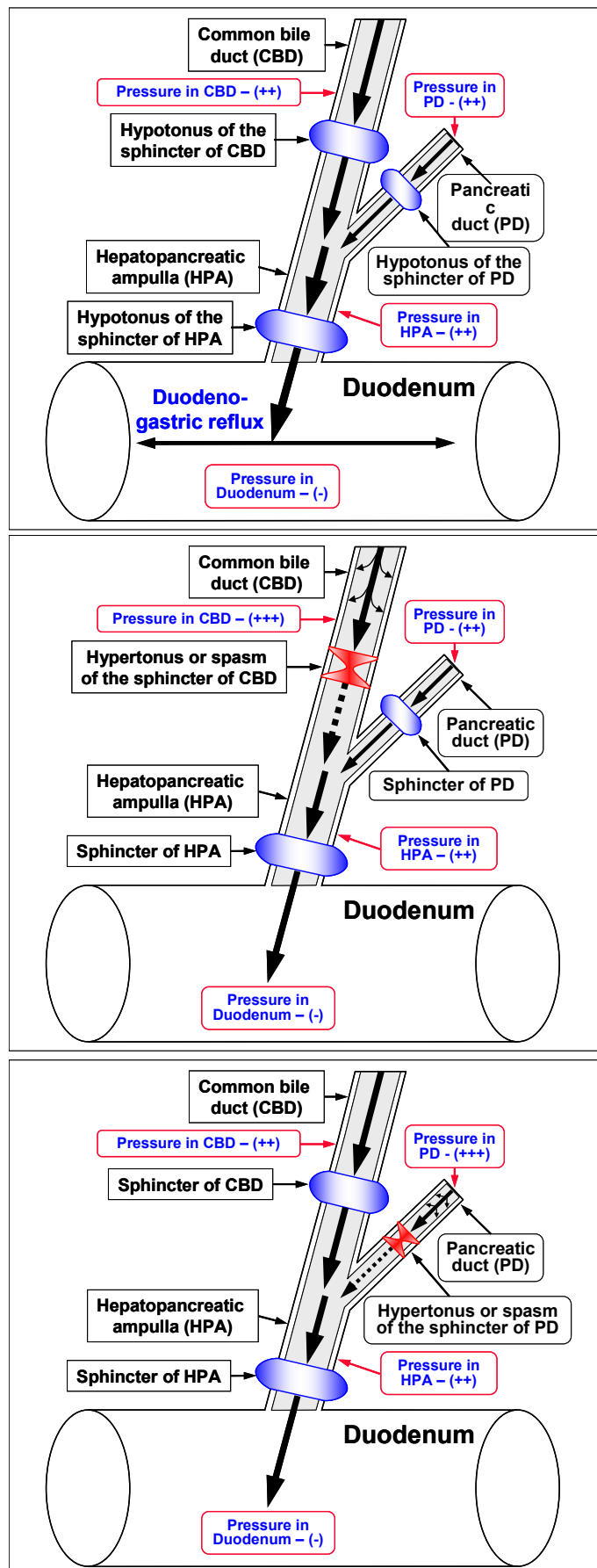


Model of functional disorders in the sphincter of Oddi in patients with biliary diseases and pancreatic diseases



Sphincter of Oddi hypomotility and duodenogastric reflux

Fig. 1. Passage of hepatic bile and pancreatic juice into the duodenum lumen in patients with biliary diseases, sphincter of Oddi hypomotility (hypomotility of the sphincter of common bile duct, sphincter of pancreatic duct and sphincter of hepatopancreatic ampulla) and duodenogastric reflux (duodenal juice) or duodenogastroesophageal reflux (duodenal juice and gastric juice).

Associated diseases: Bile reflux gastritis. Atrophic antral gastritis. Intestinal metaplasia. Duodenogastroesophageal reflux disease. Chronic esophagitis. Gastric metaplasia. Dysplasia. Esophageal cancer.

Biliary type III of sphincter of Oddi dysfunction

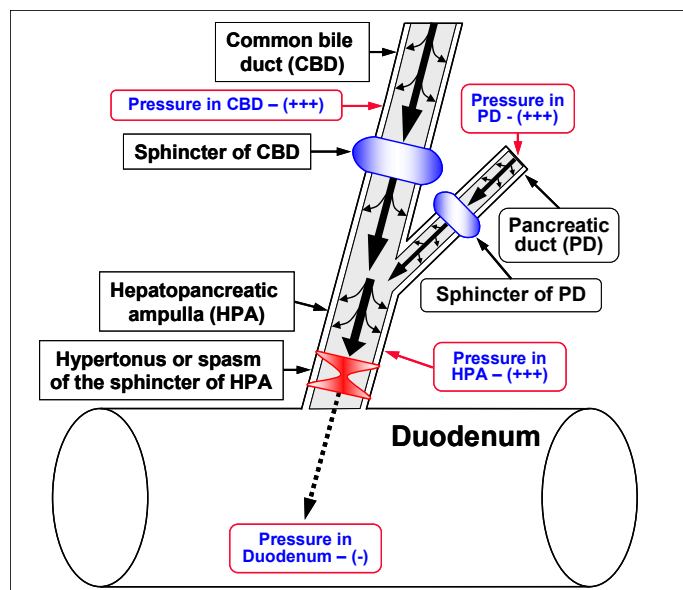
Fig. 2. Passage of hepatic bile and pancreatic juice into the duodenum lumen in patients with biliary diseases and hypertonus (spasm) of the sphincter of common bile duct (biliary type III of sphincter of Oddi dysfunction). The increase of COX-2 activity in the smooth muscle cells of the sphincter of common bile duct may be accompanied by hypertonus (spasm) formation.

Associated diseases: Chronic (spastic aseptic) cholecystitis. Cholesterol gallstone disease. Chronic calculous cholecystitis. Metaplasia.

Pancreatic type III of sphincter of Oddi dysfunction

Fig. 3. Passage of hepatic bile and pancreatic juice into the duodenum lumen in patients with biliary diseases and hypertonus (spasm) of the sphincter of pancreatic duct (pancreatic type III of sphincter of Oddi dysfunction). The increase of COX-2 activity in the smooth muscle cells of the sphincter of pancreatic duct may be accompanied by hypertonus (spasm) formation.

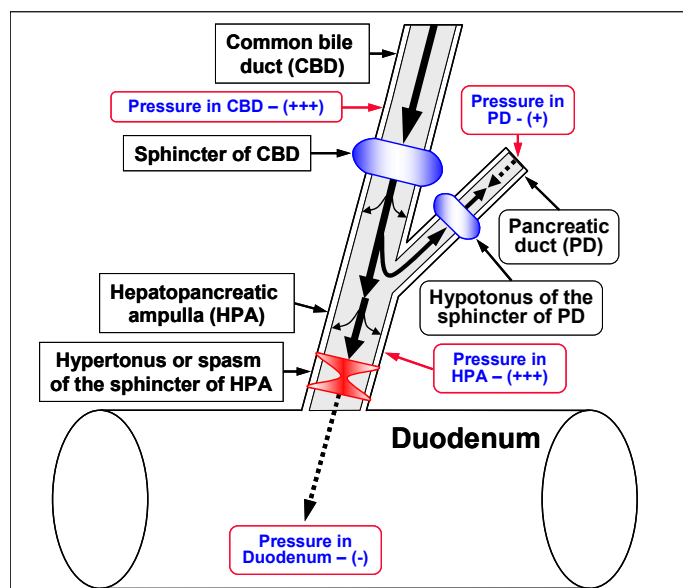
Associated diseases: Chronic (spastic aseptic) pancreatitis.



Mixed type of sphincter of Oddi dysfunction

Fig. 4. Passage of hepatic bile and pancreatic juice into the duodenum lumen in patients with biliary diseases and a **hypertonus (spasm)** of the sphincter of hepatopancreatic ampulla (**mixed type of sphincter of Oddi dysfunction**). The increase of **COX-2 activity in the smooth muscle cells** of the sphincter of hepatopancreatic ampulla may be accompanied by hypertonus (spasm) formation.

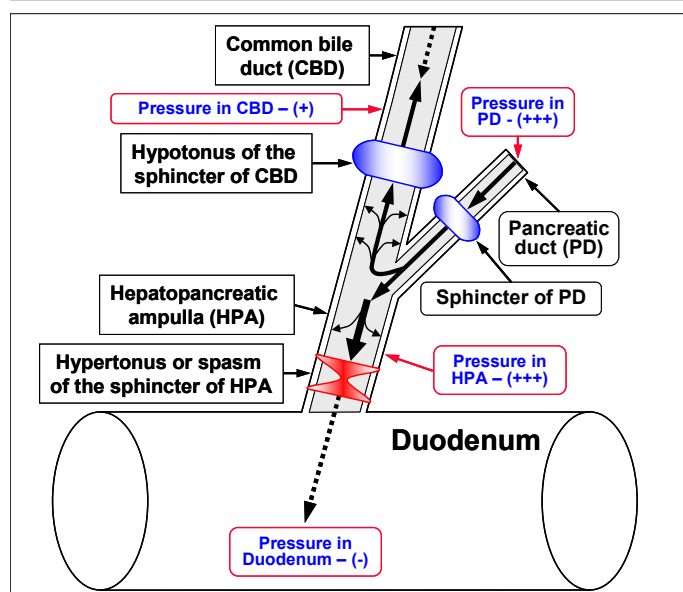
Associated diseases: Chronic (aseptic) cholecystitis. Cholesterol gallstone disease. Chronic calculous cholecystitis. Metaplasia. Chronic (aseptic) pancreatitis.



Biliopancreatic reflux (lithogenic bile)

Fig. 5. Passage of hepatic bile and pancreatic juice into the duodenum lumen in patients with biliary diseases, **hypertonus (spasm)** of the sphincter of hepatopancreatic ampulla, **hypotonus** of the sphincter of pancreatic duct and **biliopancreatic reflux** of hepatic bile into the pancreatic duct. The increase of **COX-2 activity in the smooth muscle cells** of the sphincter of hepatopancreatic ampulla may be accompanied by hypertonus (spasm) formation.

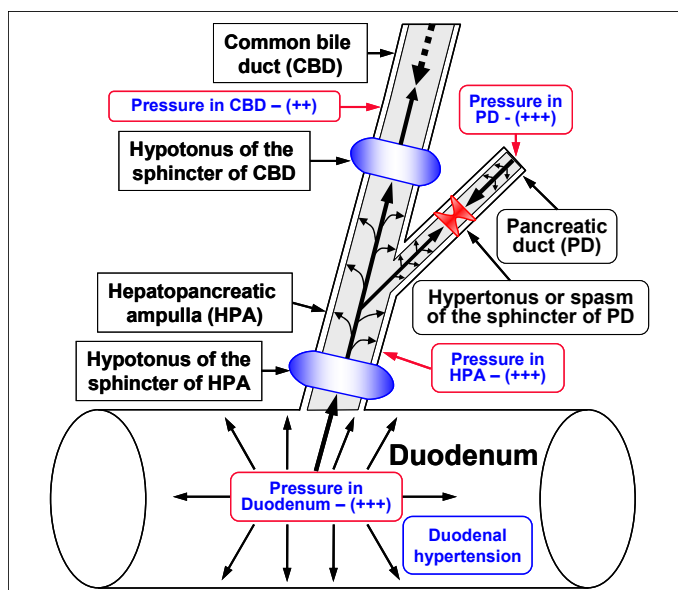
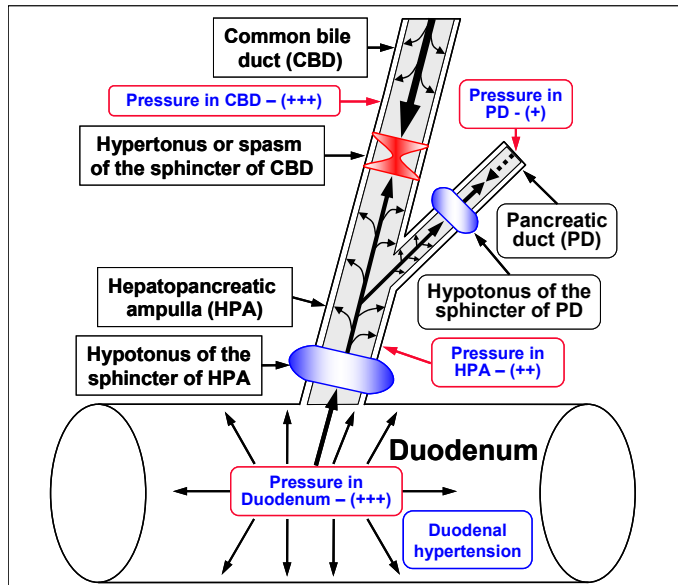
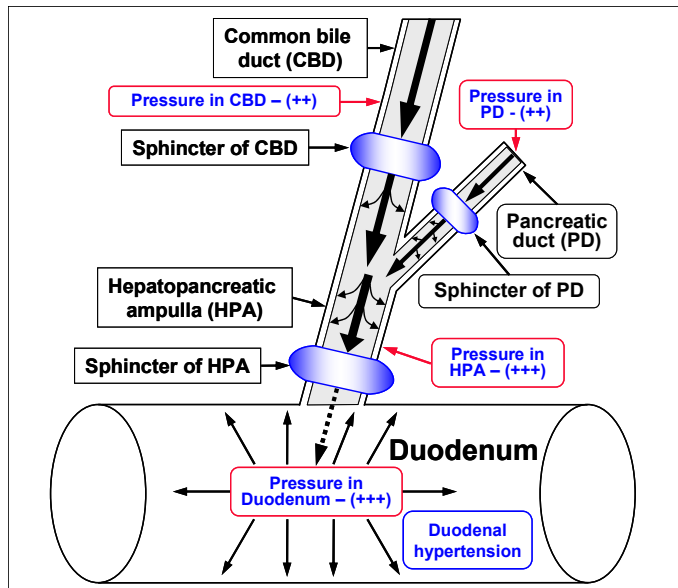
Associated diseases: Chronic biliary pancreatitis. Biliary metaplasia. Dysplasia. Pancreatic cancer.



Pancreaticobiliary reflux (pancreatic juice)

Fig. 6. Passage of hepatic bile and pancreatic juice into the duodenum lumen in patients with biliary diseases, **hypertonus (spasm)** of the sphincter of hepatopancreatic ampulla, **hypotonus** of the sphincter of common bile duct and **pancreaticobiliary reflux** of pancreatic juice into the common bile duct. The increase of **COX-2 activity in the smooth muscle cells** of the sphincter of hepatopancreatic ampulla may be accompanied by hypertonus (spasm) formation.

Associated diseases: Chronic (enzymatic) cholecystitis. Chronic calculous cholecystitis. Intestinal metaplasia. Dysplasia. Gallbladder cancer.



Syndrome of excessive bacterial growth in duodenum (duodenal hypertension)

Fig. 7. Passage of hepatic bile and pancreatic juice into the duodenum lumen in patients with biliary diseases and **duodenal hypertension** (the increase of intraluminal pressure in the duodenum – **syndrome of excessive bacterial growth in duodenum**).

Associated diseases: Gallstone disease. Chronic calculous cholecystitis. Chronic pancreatitis.

Duodenal-pancreatic reflux (duodenal juice)

Fig. 8. Passage of hepatic bile and pancreatic juice into the duodenum lumen in patients with biliary diseases, hypotonus of the sphincter of hepatopancreatic ampulla, hypotonus of the sphincter of pancreatic duct, hypertonus (spasm) of the sphincter of common bile duct, **duodenal hypertension** (the increase of intraluminal pressure in the duodenum – bacterial overgrowth) and **duodenal-pancreatic reflux** of duodenal juice into the pancreatic duct.

Associated diseases: Chronic (infectious) pancreatitis. Chronic (alcoholic infectious) pancreatitis. Chronic (acidic) pancreatitis. Metaplasia. Dysplasia. Pancreatic cancer.

Duodenal-biliary reflux (duodenal juice)

Fig. 9. Passage of hepatic bile and pancreatic juice into the duodenum lumen in patients with biliary diseases, hypotonus of the sphincter of hepatopancreatic ampulla, hypotonus of the sphincter of common bile duct, hypertonus (spasm) of the sphincter of pancreatic duct, **duodenal hypertension** (the increase of intraluminal pressure in the duodenum – bacterial overgrowth) and **duodenal-biliary reflux** of duodenal juice into the common bile duct.

Associated diseases: Chronic (infectious) cholecystitis. Mixed or Pigment (brown) gallstone disease. Chronic calculous cholecystitis. Gastric metaplasia.

Functional disorders in the sphincter of Oddi and possibly reflux associated diseases in the hepato-biliary-cholecysto-pancreatico-duodeno-gastro-esophageal region

Functional disorders in the sphincter of Oddi	Possibly reflux associated diseases
Type of reflux or dysfunction	Target organ – Gallbladder
Pancreaticobiliary reflux (pancreatic juice)	Chronic (enzymatic) cholecystitis. Chronic calculous cholecystitis. Intestinal metaplasia. Dysplasia. Gallbladder cancer.
Biliary type III of sphincter of Oddi dysfunction (spasm of sphincter of common bile duct)	Chronic (spastic aseptic) cholecystitis. Cholesterol gallstone disease. Chronic calculous cholecystitis. Metaplasia.
Duodenal-biliary reflux (duodenal juice) (\pm <i>Salmonella enterica</i> serovar Typhi)	Chronic (infectious) cholecystitis. Mixed or Pigment (brown) gallstone disease. Chronic calculous cholecystitis. Metaplasia.
Duodenal-biliary (acidic) reflux (duodenal juice and gastric juice) (\pm <i>Helicobacter pylori</i>)	Chronic (infectious) cholecystitis. Mixed or Pigment (brown) gallstone disease. Chronic calculous cholecystitis. Gastric metaplasia.
Type of reflux or dysfunction	Target organ – Pancreas
Biliopancreatic reflux (lithogenic bile)	Chronic biliary pancreatitis. Biliary metaplasia. Dysplasia. Pancreatic cancer.
Pancreatic type III of sphincter of Oddi dysfunction (spasm of sphincter of pancreatic duct)	Chronic (spastic aseptic) pancreatitis.
Duodenal-pancreatic alcohol reflux (duodenal juice and gastric juice and alcohol)	Chronic (alcoholic infectious) pancreatitis.
Duodenal-pancreatic reflux (duodenal juice) (\pm <i>Salmonella enterica</i> serovar Typhi)	Chronic (infectious) pancreatitis.
Duodenal-pancreatic (acidic) reflux (duodenal juice and gastric juice) (\pm <i>Helicobacter pylori</i>)	Chronic (acidic) pancreatitis. Metaplasia. Dysplasia. Pancreatic cancer.
Type of reflux or dysfunction	Target organ – Duodenum – Stomach – Esophagus
Duodenogastric reflux (duodenal juice)	Bile reflux gastritis. Atrophic antral gastritis. Intestinal metaplasia.
Duodenogastroesophageal reflux (duodenal juice and gastric juice)	Bile reflux gastritis. Gastroesophageal reflux disease. Chronic esophagitis. Gastric metaplasia. Dysplasia. Esophageal cancer.
Small intestinal bacterial overgrowth syndrome (duodenum) (duodenal hypertension)	Gallstone disease. Chronic calculous cholecystitis. Chronic pancreatitis.

Absorption function of a gallbladder, a functional status of the sphincter of Oddi, an anatomic configuration of hepatopancreatic ampulla of the sphincter of Oddi (Y-type, V-type or U-type) define development and prevalence of the certain type of pathology in each concrete patient with biliary diseases and pancreatic diseases.

Inactivation of chronic aseptic inflammation – Selective or nonselective COX-2 inhibitors.
 Inactivation of spasm – Selective or nonselective spasmolytics.
 Inactivation of *Helicobacter pylori* – Antibacterial drugs (Eradication).
 Inactivation of *Salmonella enterica* serovar Typhi – Antibacterial drugs (Eradication).
 Inactivation of lithogenic bile and toxic secondary hydrophobic bile acids – Ursodeoxycholic acid.
 Inactivation of pancreatic juice – Pancreatic enzymes (?) and/or Ursodeoxycholic acid (?).
 Inactivation of gastric juice (HCl) – Proton pump inhibitor (PPI) agents. Selective prokinetics.

1. **Selective COX-2 inhibitors** (celecoxib, nimesulide, etc.): **celecoxib** – 100 mg or 200 mg * 2 times per day during **5-7 days**;
2. **Nonselective COX-2 inhibitors** (ibuprofen, diclofenac sodium, indomethacin, naproxen sodium, ketoprofen, flurbiprofen, etc.): **ibuprofen** – 200 mg or 300 mg or 400 mg * 3 times per day during **5-7 days**;
3. **Selective spasmolytics** (pinaverium bromide, mebeverine hydrochloride, hycemomone, hyoscine butylbromide, etc.): **hycemomone** – 200 mg or 400 mg or 600 mg * 3 times per day during **5-7 days**;
4. **Nonselective spasmolytics** (drotaverine hydrochloride, papaverine hydrochloride, fempiverinium, etc.): **drotaverine hydrochloride** – 40 mg or 60 mg or 80 mg * 3 times per day during **5-7 days**;
5. **Antibacterial drugs** (ciprofloxacin, clarithromycin, amoxicillin, metronidazole, erythromycin, doxycycline, co-trimoxazole, etc.): **ciprofloxacin** – 500 mg * 2 times per day during **5 days**;
6. **Ursodeoxycholic acid**: **ursodeoxycholic acid** – 750 mg * 1 time before going to bed – **14-30-45 days**.
7. **Pancreatic enzymes** (mezym forte, panzynorm forte, pancreoflat, festal, kreon, etc.): **kreon 10000** – 1 capsule or 2 capsules * 2-4 times per day during meal during **7-14-30 days**;
8. **Proton pump inhibitor (PPI) agents** (esomeprazole, lansoprazole, omeprazole, pantoprazole, rabeprazole, dexlansoprazole): **rabeprazole** – 20 mg * once daily – **during 4-8 weeks**.
9. **Selective prokinetics** (domperidone, cizapride, metoclopramide, etc.): **domperidone** – 10 mg * 3-4 times per day before meal and at bedtime during **14 days**.

The universal algorithm of the pathogenetic treatment of symptomatic (with biliary pain) biliary diseases with concomitant functional disorders in the sphincter of Oddi:

- 1) **selective COX-2 inhibitors** (celecoxib or nimesulide, etc.):
celecoxib – 100 mg or 200 mg * 2 times per day during 5-7 days,
- +
2) **selective spasmolytics** (hycemomone or mebeverine hydrochloride or hyoscine butylbromide or pinaverium bromide, etc.):
hycemomone – 200 mg or 400 mg or 600 mg * 3 times per day during 5-7 days;
- +
3) **antibacterial drugs** (ciprofloxacin [for eradication of *Salmonella enterica ser. Typhi*] or clarithromycin + amoxicillin or metronidazole [for eradication of *Helicobacter pylori*], etc.):
ciprofloxacin – 500 mg * 2 times per day during 5 days,
- 4) **after 5 days of treatment** (1+2+3):
ursodeoxycholic acid – 750 mg 1 time before going to bed – 30-45 days.

Absorption function of a gallbladder, a functional status of the sphincter of Oddi, an anatomic configuration of hepatopancreatic ampulla of the sphincter of Oddi (Y-type, V-type or U-type) define development and prevalence of the certain type of pathology in each concrete patient with biliary diseases and pancreatic diseases.

Therefore, depending on dysfunction (hyper tonus) or relaxation (hypo tonus) of the human sphincter of Oddi, depending on anatomic configurations of the human sphincter of Oddi (Y-type, V-type or U-type) and length of common channel (>5 mm, 2-5 mm or <2 mm) of the human sphincter of Oddi, different pathology will form in patients with biliary diseases after cholecystectomy in hepato-biliary-pancreatico-duodenal-gastric zone.

The presented data and this algorithm of pathogenetic treatment of biliary diseases with concomitant functional disorders in sphincter of Oddi may help diminish the duration of disease period and the quantity of patients with biliary diseases by 30-40%. Also, the remission period will be increased up to 18-24 months.

The pathogenetic correction of metabolic and morpho-functional disturbances in the gallbladder and liver:

- in patients with **gallbladder dysfunction** helps decrease the risk of appearance of the **chronic acalculous cholecystitis without biliary sludge**,
- in patients with **chronic acalculous cholecystitis without biliary sludge** helps decrease the risk of appearance of the **chronic acalculous cholecystitis with biliary sludge**,
- in patients with **chronic acalculous cholecystitis with biliary sludge** helps decrease the risk of appearance of the **chronic calculous cholecystitis**,
- in patients with **chronic calculous cholecystitis** helps decrease the risk of appearance of the **acute calculous cholecystitis**,

- in patients after cholecystectomy helps decrease the risk of appearance of the choledocholithiasis,
- ◆ in patients with pancreaticobiliary reflux of pancreatic juice into common bile duct and the gallbladder (hypomotility of the sphincter of pancreatic duct and sphincter of common bile duct) helps decrease the risk of appearance of the chronic acalculous (enzymatic) cholecystitis and chronic calculous cholecystitis,
- ◆ in patients with spasm of the sphincter of common bile duct helps decrease the risk of appearance of the biliary type III of sphincter of Oddi dysfunction, the chronic acalculous (aseptic spastic) cholecystitis and chronic calculous cholecystitis,
- ◆ in patients with duodenal hypertension (the increase of intraluminal pressure in the duodenum – the small intestinal bacterial overgrowth syndrome) and duodenal-biliary reflux of duodenal juice into the common bile duct (hypomotility of the sphincter of hepatopancreatic ampulla and sphincter of common bile duct) and into the gallbladder helps decrease the risk of appearance of the chronic cholangitis, chronic acalculous (infectious) cholecystitis and chronic calculous cholecystitis, mixed gallstone disease or pigment (brown) gallstone disease,
- in patients with biliopancreatic reflux of lithogenic bile into the pancreatic duct (hypomotility of the sphincter of common bile duct and sphincter of pancreatic duct) helps decrease the risk of appearance of the chronic biliary (bile) pancreatitis and pancreatic cancer,
- in patients with spasm of the sphincter of pancreatic duct helps decrease the risk of appearance of the pancreatic type III of sphincter of Oddi dysfunction and chronic (aseptic) pancreatitis,
- in patients with duodenal hypertension (the increase of intraluminal pressure in the duodenum – the small intestinal bacterial overgrowth syndrome) and duodenal-pancreatic reflux of duodenal juice into the pancreas (hypomotility of the sphincter of hepatopancreatic ampulla and sphincter of pancreatic duct) helps decrease the risk of appearance of the chronic alcoholic (infectious) pancreatitis, chronic (chymous infectious) pancreatitis, chronic (acidic) pancreatitis,
- in patients with duodenogastric bile reflux (hypomotility of the sphincter of common bile duct and sphincter of hepatopancreatic ampulla) of duodenal juice (mixture of duodenal bile and pancreatic juice) helps decrease the risk of appearance of the atrophic antral gastritis (bile reflux gastritis),
- in patients with duodenogastroesophageal bile reflux (hypomotility of the sphincter of common bile duct and sphincter of hepatopancreatic ampulla, and hypomotility of the lower esophageal sphincter) of duodenal juice (mixture of duodenal bile and pancreatic juice and gastric juice) helps decrease the risk of appearance of the esophagitis and gastro-esophageal-reflux-disease (bile reflux esophagitis),
- ◆ in patients with small intestinal bacterial overgrowth syndrome (duodenal hypertension) helps decrease the risk of appearance of the gallstone disease, chronic calculous cholecystitis and chronic pancreatitis.

This algorithm of pathogenetic treatment of biliary diseases with concomitant functional disorders in sphincter of Oddi may help:

1. Effectively to stop the biliary pain and dyspeptic syndrome within 1-3 days;
2. To block the intensity of chronic aseptic inflammation in the gallbladder wall within 7-10 days, i.e. to decrease the thickness of gallbladder wall from 4-5 mm up to 2 mm;
3. Complete disorganization and elimination of biliary sludge within 10-14 days;
4. To restore the accumulation function of liver and the excretion function of liver within 10-14 days;
5. To restore the absorption function and the concentrating function and the evacuation function of gallbladder within 10-14 days;
6. To increase the duration of complete clinical remission period up to 2-4 years.

These data will help diminish the quantity of patients with biliary diseases (the gallbladder dysfunction, the chronic acalculous cholecystitis (aseptic spastic) without biliary sludge, the chronic acalculous (enzymatic) cholecystitis, the chronic acalculous (infectious) cholecystitis, the chronic acalculous cholecystitis with biliary sludge, the chronic calculous cholecystitis, the acute calculous cholecystitis, the choledocholithiasis) and the quantity of patients with pancreatic diseases (the chronic biliary pancreatitis, the chronic (aseptic) pancreatitis, the chronic alcoholic (infectious) pancreatitis), the chronic (chymous infectious) pancreatitis, the chronic (acidic) pancreatitis and the quantity of patients with gastro-esophageal-reflux-disease, and, also, the quantity of patients after cholecystectomy by 30-40% after 18-24 months in different countries of the North America, Central America and South America, Europe and Asia Pacific, Africa and Middle East.

Pancreaticobiliary reflux – Biliopancreatic reflux – Choledocho-pancreatic reflux – Duodenal-biliary reflux – Duodenal-pancreatic reflux

1. **Beltrán MA.** Current knowledge on pancreaticobiliary reflux in normal pancreaticobiliary junction. *Int J Surg.* 2012; **10(4)**: 190-193.
2. **Beltrán MA.** Pancreaticobiliary reflux in patients with a normal pancreaticobiliary junction: Pathologic implications. *World J Gastroenterol* 2011; **17(8)**: 953-962.
3. **Beltrán MA, Contreras MA, Cruces KS.** Pancreaticobiliary reflux in patients with and without cholelithiasis: is it a normal phenomenon? *World J Surg.* 2010; **34(12)**: 2915-2921.
4. **Kamisawa T, Suyama M, Fujita N, Maguchi H, Hanada K, Ikeda S, Igarashi Y, Itoi T, Kida M, Honda G, Sai J, Horaguchi J, Takahashi K, Sasaki T, Takuma K, Itokawa F, Ando H, Takehara H; Committee of Diagnostic Criteria of The Japanese Study Group on Pancreaticobiliary.** Pancreatobiliary reflux and the length of a common channel. *J Hepatobiliary Pancreat Sci.* 2010; **17(6)**: 865-870.
5. **Kamisawa T, Honda G, Kurata M, Tokura M, Tsuruta K.** Pancreatobiliary disorders associated with pancreaticobiliary maljunction. *Dig Surg.* 2010; **27(2)**: 100-104.
6. **van Geenen EJ, van der Peet DL, Bhagirath P, Mulder CJ, Bruno MJ.** Etiology and diagnosis of acute biliary pancreatitis. *Nat Rev Gastroenterol Hepatol.* 2010; **7(9)**: 495-502.
7. **Horiguchi S, Kamisawa T.** Major duodenal papilla and its normal anatomy. *Dig Surg.* 2010; **27(2)**: 90-93.
8. **Kamisawa T, Takuma K, Anjiki H, Egawa N, Kurata M, Honda G, Tsuruta K, Sasaki T.** Pancreatobiliary maljunction. *Clin Gastroenterol Hepatol.* 2009; **7(11 Suppl)**: S84-S88.
9. **Xian GZ, Wu SD, Chen CC, Su Y.** Western blotting in the diagnosis of duodenal-biliary and pancreaticobiliary refluxes in biliary diseases. *Hepatobiliary Pancreat Dis Int.* 2009; **8(6)**: 608-613.
10. **Toouli J.** Sphincter of Oddi: Function, dysfunction, and its management. *J Gastroenterol Hepatol.* 2009; **24 Suppl 3**: S57-S62.
11. **Sakamoto H, Mutoh H, Ido K, Satoh S, Kumagai M, Hayakawa H, Tamada K, Sugano K.** Intestinal metaplasia in gallbladder correlates with high amylase levels in bile in patients with a morphologically normal pancreaticobiliary duct. *Hum Pathol.* 2009; **40(12)**: 1762-1767.
12. **Wang GJ, Gao CF, Wei D, Wang C, Ding SQ.** Acute pancreatitis: etiology and common pathogenesis. *World J Gastroenterol.* 2009; **15(12)**: 1427-1430.
13. **Siqin D, Wang C, Zhou Z, Li Y.** The key event of acute pancreatitis: pancreatic duct obstruction and bile reflux, not a single one can be omitted. *Med Hypotheses.* 2009; **72(5)**: 589-591.
14. **Kamisawa T, Kurata M, Honda G, Tsuruta K, Okamoto A.** Biliopancreatic reflux – pathophysiology and clinical implications. *J Hepatobiliary Pancreat Surg.* 2009; **16(1)**: 19-24.
15. **Kamisawa T, Anjiki H, Egawa N, Kurata M, Honda G, Tsuruta K.** Diagnosis and clinical implications of pancreaticobiliary reflux. *World J Gastroenterol.* 2008; **14(43)**: 6622-6626.
16. **Kamisawa T, Tu Y, Egawa N, Tsuruta K, Okamoto A, Matsukawa M.** Pancreas divisum in pancreaticobiliary maljunction. *Hepatogastroenterology.* 2008; **55(81)**: 249-253.
17. **Horaguchi J, Fujita N, Noda Y, Kobayashi G, Ito K, Takasawa O, Obana T, Endo T, Nakahara K, Ishida K, Yonechi M, Hirasawa D, Suzuki T, Sugawara T, Ohhira T, Onochi K, Harada Y.** Amylase levels in bile in patients with a morphologically normal pancreaticobiliary ductal arrangement. *J Gastroenterol.* 2008; **43(4)**: 305-311.
18. **Zhang ZH, Wu SD, Wang B, Su Y, Jin JZ, Kong J, Wang HL.** Sphincter of Oddi hypomotility and its relationship with duodenal-biliary reflux, plasma motilin and serum gastrin. *World J Gastroenterol.* 2008; **14(25)**: 4077-4081.
19. **Beltrán MA, Vracko J, Cumsille MA, Cruces KS, Almonacid J, Danilova T.** Occult pancreaticobiliary reflux in gallbladder cancer and benign gallbladder diseases. *J Surg Oncol.* 2007; **96(1)**: 26-31.
20. **Kamisawa T, Tu Y, Nakajima H, Egawa N, Tsuruta K, Okamoto A, Matsukawa M.** Acute pancreatitis and a long common channel. *Abdom Imaging.* 2007; **32(3)**: 365-369.
21. **Wu SD, Yu H, Wang HL, Su Y, Zhang ZH, Sun SL, Kong J, Tian Y, Tian Z, Wei Y, Jin HX, Jin JZ.** The relationship between Oddi's sphincter and bile duct pigment gallstone. *Zhonghua Wai Ke Za Zhi.* 2007; **45(1)**: 58-61. *Article in Chinese*
22. **Sai JK, Suyama M, Kubokawa Y, Nobukawa B.** Gallbladder carcinoma associated with pancreaticobiliary reflux. *World J Gastroenterol.* 2006; **12(40)**: 6527-6530.
23. **Kamisawa T, Okamoto A.** Biliopancreatic and pancreaticobiliary refluxes in cases with and without pancreaticobiliary maljunction: diagnosis and clinical implications. *Digestion.* 2006; **73(4)**: 228-236.
24. **Woods CM, Mawe GM, Toouli J, Saccone GT.** The sphincter of Oddi: understanding its control and function. *Neurogastroenterol Motil.* 2005; **17 Suppl 1**: 31-40.
25. **Sai JK, Suyama M, Nobukawa B, Kubokawa Y, Yokomizo K, Sato N.** Precancerous mucosal changes in the gallbladder of patients with occult pancreaticobiliary reflux. *Gastrointest Endosc.* 2005; **61(2)**: 264-268.
26. **Itoi T, Tsuchida A, Itokawa F, Sofuni A, Kurihara T, Tsuchiya T, Moriyasu F, Kasuya K, Serizawa H.** Histologic and genetic analysis of the gallbladder in patients with occult pancreaticobiliary reflux. *Int J Mol Med.* 2005; **15(3)**: 425-430.
27. **Spicák J.** Etiological factors of acute pancreatitis. *Vnitř Lek.* 2002; **48(9)**: 829-841. *Article in Czech.*

Duodenogastric reflux – Duodenogastroesophageal reflux – Cholecystectomy

1. **Chen SL**, Ji JR, Xu P, Cao ZJ, Mo JZ, Fang JY, Xiao SD. Effect of domperidone therapy on nocturnal dyspeptic symptoms of functional dyspepsia patients. *World J Gastroenterol*. 2010; **16(5)**: 613-617.
2. **Stefănescu G**, Bălan G, Stanciu C. The relationship between bile reflux and symptoms in patients with gallstones before and after cholecystectomy. *Rev Med Chir Soc Med Nat Iasi*. 2009; **113(3)**: 698-703. (in Romanian)
3. **Kunsch S**, Neesse A, Huth J, Steinkamp M, Klaus J, Adler G, Gress TM, Ellenrieder V. Increased duodeno-gastro-esophageal reflux (DGER) in symptomatic GERD patients with a history of cholecystectomy. *Z Gastroenterol*. 2009; **47(8)**: 744-748.
4. **Santarelli L**, Gabrielli M, Candelli M, Cremonini F, Nista EC, Cammarota G, Gasbarrini G, Gasbarrini A. Post-cholecystectomy alkaline reactive gastritis: a randomized trial comparing sucralfate versus ranitidine or no treatment. *Eur J Gastroenterol Hepatol*. 2003; **15(9)**: 97975-97979.
5. **Fountos A**, Chrysos E, Tsiaoussis J, Karkavitsas N, Zoras OJ, Katsamouris A, Xynos E. Duodenogastric reflux after biliary surgery: scintigraphic quantification and improvement with erythromycin. *ANZ J Surg*. 2003; **73(6)**: 400-403.
6. **Nakamura M**, Haruma K, Kamada T, Mihara M, Yoshihara M, Imagawa M, Kajiyama G. Duodenogastric reflux is associated with antral metaplastic gastritis. *Gastrointest Endosc*. 2001; **53(1)**: 53-59.
7. **Manifold DK**, Anggiansah A, Owen WJ. Effect of cholecystectomy on gastroesophageal and duodenogastric reflux. *Am J Gastroenterol*. 2000; **95(10)**: 2746-2750.
8. **Castedal M**, Björnsson E, Gretarsdottir J, Fjälling M, Abrahamsson H. Scintigraphic assessment of interdigestive duodenogastric reflux in humans: distinguishing between duodenal and biliary reflux material. *Scand J Gastroenterol*. 2000; **35(6)**: 590-598.

Duodenogastric reflux – Duodenogastroesophageal reflux Ursodeoxycholic acid treatment of bile reflux gastritis

1. **Thao TD**, Ryu HC, Yoo SH, Rhee DK. Antibacterial and anti-atrophic effects of a highly soluble, acid stable UDCA formula in Helicobacter pylori-induced gastritis. *Biochem Pharmacol*. 2008; **75(11)**: 2135-2146.
2. **Piepoli AL**, Caroppo R, Armentano R, Caruso ML, Guerra V, Maselli MA. Tauroursodeoxycholic acid reduces damaging effects of taurodeoxycholic acid on fundus gastric mucosa. *Arch Physiol Biochem*. 2002; **110(3)**: 197-202.
3. **Ozkaya M**, Erten A, Sahin I, Engin B, Ciftci A, Cakal E, Caydere M, Demirbas B, Ustun H. The effect of ursodeoxycholic acid treatment on epidermal growth factor in patients with bile reflux gastritis. *Turk J Gastroenterol* 2002; **13(4)**: 198-202.
4. **Scarpa PJ**, Cappell MS. Treatment with ursodeoxycholic acid of bile reflux gastritis after cholecystectomy. *J Clin Gastroenterol* 1991; **13**: 601-603.
5. **Pazzi P**, Scalia S, Stabellini G. Bile reflux gastritis in patients without prior gastric surgery: Therapeutic effects of ursodeoxycholic acid. *Cur Ther Res* 1989; **45**: 476-680.
6. **Rosman AS**. Efficacy of UDCA in treating bile reflux gastritis. *Gastroenterology*. 1987; **92(1)**: 269-272.
7. **Pazzi P**, Stabellini G. Effect of UDCA on biliary dyspepsia in patients without gallstones. *Cur Ther Res* 1985; **37**: 685-690.
8. **Stefaniwisky AB**, Tint GS. Ursodeoxycholic acid treatment of bile reflux gastritis. *Gastroenterology* 1985; **89**: 1000-1004.

Ursodeoxycholic acid treatment of pancreatitis

1. **Venneman NG**, van Erpecum KJ. Gallstone disease: Primary and secondary prevention. *Best Pract Res Clin Gastroenterol*. 2006; **20(6)**: 1063-1073.
2. **Venneman NG**, vanBerge-Henegouwen GP, van Erpecum KJ. Pharmacological manipulation of biliary water and lipids: potential consequences for prevention of acute biliary pancreatitis. *Curr Drug Targets Immune Endocr Metabol Disord*. 2005; **5(2)**: 193-198.
3. **Saraswat VA**, Sharma BC, Agarwal DK, Kumar R, Negi TS, Tandon RK. Biliary microlithiasis in patients with idiopathic acute pancreatitis and unexplained biliary pain: response to therapy. *J Gastroenterol Hepatol*. 2004; **19(10)**: 1206-1211.
4. **Fischer S**, Müller I, Zündt BZ, Jüngst C, Meyer G, Jüngst D. Ursodeoxycholic acid decreases viscosity and sedimentable fractions of gallbladder bile in patients with cholesterol gallstones. *Eur J Gastroenterol Hepatol*. 2004; **16(3)**: 305-311.
5. **Tsubakio K**, Kiriya K, Matsushima N, Taniguchi M, Shizusawa T, Katoh T, Manabe N, Yabu M, Kanayama Y, Himeno S. Autoimmune pancreatitis successfully treated with ursodeoxycholic acid. *Intern Med*. 2002; **41(12)**: 1142-1146.
6. **Testoni PA**, Caporuscio S, Bagnolo F, Lella F. Idiopathic recurrent pancreatitis: long-term results after ERCP, endoscopic sphincterotomy, or ursodeoxycholic acid treatment. *Am J Gastroenterol*. 2000; **95(7)**: 1702-7.

Pancreatobiliary reflux – Intestinal metaplasia in gallbladder. Gallbladder cancer.

**Biliopancreatic reflux – Pancreatic cancer (papillary, tubular or cystic adenocarcinoma).
Intraductal papillary carcinoma. Intraductal tubular carcinoma.**

1. **Kamisawa T, Honda G, Kurata M, Tokura M, Tsuruta K.** Pancreatobiliary disorders associated with pancreaticobiliary maljunction. *Dig Surg.* 2010; **27(2)**: 100-4.
2. **Kamisawa T, Takuma K, Anjiki H, Egawa N, Kurata M, Honda G, Tsuruta K, Sasaki T.** Pancreaticobiliary maljunction. *Clin Gastroenterol Hepatol.* 2009; **7(11 Suppl)**: S84-S88.
3. **Sakamoto H, Mutoh H, Ido K, Satoh S, Kumagai M, Hayakawa H, Tamada K, Sugano K.** Intestinal metaplasia in gallbladder correlates with high amylase levels in bile in patients with a morphologically normal pancreaticobiliary duct. *Hum Pathol.* 2009; **40(12)**: 1762-1767.
4. **Kasuya K, Nagakawa Y, Matsudo T, Ozawa T, Tsuchida A, Aoki T, Itoi T, Itokawa F.** p53 gene mutation and p53 protein overexpression in a patient with simultaneous double cancer of the gallbladder and bile duct associated with pancreaticobiliary maljunction. *J Hepatobiliary Pancreat Surg.* 2009; **16(3)**: 376-381.
5. **Siqin D, Wang C, Zhou Z, Li Y.** The key event of acute pancreatitis: pancreatic duct obstruction and bile reflux, not a single one can be omitted. *Med Hypotheses.* 2009; **72(5)**: 589-591.
6. **Funabiki T, Matsubara T, Miyakawa S, Ishihara S.** Pancreaticobiliary maljunction and carcinogenesis to biliary and pancreatic malignancy. *Langenbecks Arch Surg.* 2009; **394(1)**: 159-169.
7. **Wang GJ, Gao CF, Wei D, Wang C, Ding SQ.** Acute pancreatitis: etiology and common pathogenesis. *World J Gastroenterol.* 2009; **15(12)**: 1427-1430.
8. **Kamisawa T, Anjiki H, Egawa N, Kurata M, Honda G, Tsuruta K.** Diagnosis and clinical implications of pancreaticobiliary reflux. *World J Gastroenterol.* 2008; **14(43)**: 6622-6626.
9. **Kamisawa T, Tu Y, Egawa N, Tsuruta K, Okamoto A, Matsukawa M.** Pancreas divisum in pancreaticobiliary maljunction. *Hepatogastroenterology.* 2008; **55(81)**: 249-253.
10. **Horaguchi J, Fujita N, Noda Y, Kobayashi G, Ito K, Takasawa O, Obana T, Endo T, Nakahara K, Ishida K, Yonechi M, Hirasawa D, Suzuki T, Sugawara T, Ohhira T, Onochi K, Harada Y.** Amylase levels in bile in patients with a morphologically normal pancreaticobiliary ductal arrangement. *J Gastroenterol.* 2008; **43(4)**: 305-311.
11. **Inagaki M, Goto J, Suzuki S, Ishizaki A, Tanno S, Kohgo Y, Tokusashi Y, Miyokawa N, Kasai S.** Gallbladder carcinoma associated with occult pancreaticobiliary reflux in the absence of pancreaticobiliary maljunction. *J Hepatobiliary Pancreat Surg.* 2007; **14(5)**: 529-533.
12. **Kamisawa T, Okamoto A.** Biliopancreatic and pancreaticobiliary refluxes in cases with and without pancreaticobiliary maljunction: diagnosis and clinical implications. *Digestion.* 2006; **73(4)**: 228-236.
13. **Sai JK, Suyama M, Kubokawa Y, Nobukawa B.** Gallbladder carcinoma associated with pancreaticobiliary reflux. *World J Gastroenterol.* 2006; **12(40)**: 6527-6530.
14. **Adachi T, Tajima Y, Kuroki T, Mishima T, Kitasato A, Fukuda K, Tsutsumi R, Kanematsu T.** Bile-reflux into the pancreatic ducts is associated with the development of intraductal papillary carcinoma in hamsters. *J Surg Res.* 2006; **136(1)**: 106-111.
15. **Itoi T, Tsuchida A, Itokawa F, Sofuni A, Kurihara T, Tsuchiya T, Moriyasu F, Kasuya K, Serizawa H.** Histologic and genetic analysis of the gallbladder in patients with occult pancreaticobiliary reflux. *Int J Mol Med.* 2005; **15(3)**: 425-430.
16. **Sai JK, Suyama M, Nobukawa B, Kubokawa Y, Sato N.** Severe dysplasia of the gallbladder associated with occult pancreaticobiliary reflux. *J Gastroenterol.* 2005; **40(7)**: 756-760.
17. **Sai JK, Suyama M, Nobukawa B, Kubokawa Y, Yokomizo K, Sato N.** Precancerous mucosal changes in the gallbladder of patients with occult pancreaticobiliary reflux. *Gastrointest Endosc.* 2005; **61(2)**: 264-268.
18. **Sano T, Kamiya J, Nagino M, Uesaka K, Oda K, Kanai M, Nimura Y.** Bile duct carcinoma arising in metaplastic biliary epithelium of the intestinal type: a case report. *Hepatogastroenterology.* 2003; **50(54)**: 1883-1885.
19. **Matsumoto Y, Fujii H, Itakura J, Matsuda M, Yang Y, Nobukawa B, Suda K.** Pancreaticobiliary maljunction: pathophysiological and clinical aspects and the impact on biliary carcinogenesis. *Langenbecks Arch Surg.* 2003; **88(2)**: 122-131.
20. **Spicák J.** Etiological factors of acute pancreatitis. *Vnitr Lek.* 2002; **48(9)**: 829-841. Article in Czech
21. **Talamini G.** Duodenal acidity may increase the risk of pancreatic cancer in the course of chronic pancreatitis: an etiopathogenetic hypothesis. *JOP. J Pancreas (Online).* 2005; **6(2)**: 122-127.
22. **Kawiorski W, Herman RM, Legutko J.** Pathogenesis and significance of gastroduodenal reflux. *Przegl Lek.* 2001; **58(1)**: 38-44. Article in Polish
23. **Johansen C, Chow WH, Jorgensen T, Mellemejkjaer L, Engholm G, Olsen JH.** Risk of colorectal cancer and other cancers in patients with gallstones. *Gut* 1996; **39(3)**: 439-443.
24. **Chow WH, Johansen C, Gridley G, Mellemejkjaer L, Olsen JH, Fraumeni JF.** Gallstones, cholecystectomy and risk of cancers of the liver, biliary tract and pancreas. *Br J Cancer* 1999; **79(3-4)**: 640-644.
25. **Jung B, Vogt T, Mathieudaude F, Welsh J, McClland M, Trenkle T, Weitzel C, Kullmann F.** Estrogen-responsive RING finger mRNA induction in gastrointestinal carcinoma cells following bile acid treat-

- ment. *Carcinogenesis* 1998; **19(11)**: 1901-1906.
26. **Delgiorno KE**, Hall JC, Takeuchi KK, Pan FC, Halbrook CJ, Washington MK, Olive KP, Spence J, Sipos B, Wright CV, Wells JM, Crawford HC. **Identification and manipulation of biliary metaplasia in pancreatic tumors.** *Gastroenterology*. 2013;
 27. **Letelier P**, Brebi P, Tapia O, Roa JC. **DNA promoter methylation as a diagnostic and therapeutic biomarker in gallbladder cancer.** *Clin Epigenetics*. 2012; **4(1)**: 1-11.
 28. **Qu K**, Liu SN, Chang HL, Liu C, Xu XS, Wang RT, Zhou L, Tian F, Wei JC, Tai MH, Meng FD. **Gallbladder cancer: a subtype of biliary tract cancer which is a current challenge in China.** *Asian Pacific J Cancer Prev*. 2012; **13(4)**: 1317-1320.
 29. **Toledo C**, Matus CE, Barraza X, Arroyo P, Ehrenfeld P, Figueroa CD, Bhoola KD, del Pozo M, Poblete MT. **Expression of HER2 and bradykinin B1 receptors in precursor lesions of gallbladder carcinoma.** *World J Gastroenterol*. 2012; **18(11)**: 1208-1215.
 30. **Mazlum M**, Dilek FH, Yener AN, Tokyol C, Aktepe F, Dilek ON. **Profile of gallbladder diseases diagnosed at Afyon Kocatepe University: a retrospective study.** *Turkish J Pathol*. 2011; **27(1)**: 23-30.
 31. **Ono S**, Fumino S, Iwai N. **Implications of intestinal metaplasia of the gallbladder in children with pancreaticobiliary maljunction.** *Pediatr Surg Int*. 2011; **27(3)**: 237-240.
 32. **Khan MR**, Raza SA, Ahmad Z, Naeem S, Pervez S, Siddiqui AA, Ahmed M, Azami R. **Gallbladder intestinal metaplasia in Pakistani patients with gallstones.** *Int J Surg*. 2011; **9(6)**: 482-485.
 33. **Roa JC**, Tapia O, Cakir A, Basturk O, Dursun N, Akdemir D, Saka B, Losada H, Bagci P, Adsay NV. **Squamous cell and adenosquamous carcinomas of the gallbladder: clinicopathological analysis of 34 cases identified in 606 carcinomas.** *Modern Pathology*. 2011; **24(8)**: 1069-1078.
 34. **Lee SH**, Lee DS, You IY, Jeon WJ, Park SM, Youn SJ, Choi JW, Sung R. **Histopathologic analysis of adenoma and adenoma-related lesions of the gallbladder.** *Korean J Gastroenterol*. 2010; **55(2)**: 119-126.
 35. **Meirelles-Costa ALA**, Bresciani CJC, Perez RO, Bresciani BH, Siqueira SAC, Cecconello I. **Are histological alterations observed in the gallbladder precancerous lesions?** *Clinics*. 2010; **65(2)**:143-150.
 36. **Fernandes JE**, Franco MI, Suzuki RK, Tavares NM, Bromberg SH. **Intestinal metaplasia in gallbladders: prevalence study.** *Sao Paulo Med J*. 2008; **126(4)**: 220-222.
 37. **Stancu M**, Caruntu ID, Giusca S, Dobrescu G. **Hyperplasia, metaplasia, dysplasia and neoplasia lesions in chronic cholecystitis – a morphologic study.** *Rom J Morph Embry*. 2007; **48(4)**: 335-342.
 38. **Maesawa C**, Ogasawara S, Yashima-Abo A, Kimura T, Kotani K, Masuda S, Nagata Y, Iwaya T, Suzuki K, Oyake T, Akiyama Y, Kawamura H, Masuda T. **Aberrant maspin expression in gallbladder epithelium is associated with intestinal metaplasia in patients with cholelithiasis.** *J Clin Pathol*. 2006; **59(3)**: 328-330.

Helicobacter pylori – Salmonella enterica serovar Typhi – Gallbladder cancer – Pancreatic cancer

1. **Risch HA**, Lu L, Wang J, Zhang W, Ni Q, Gao YT, Yu H. **ABO blood group and risk of pancreatic cancer: a study in Shanghai and meta-analysis.** *Am J Epidemiol*. 2013; **177(12)**: 1326-1337.
2. **Zhou D**, Guan WB, Wang JD, Zhang Y, Gong W, Quan ZW. **A comparative study of clinicopathological features between chronic cholecystitis patients with and without Helicobacter pylori infection in gallbladder mucosa.** *PLoS One*. 2013; **8(7)**: e70265.
3. **Lee HK**, Kim H, Kim HK, Cho YS, Kim BW, Han SW, Maeng LS, Chae HS, Kim HN. **The relationship between gastric juice nitrate/nitrite concentrations and gastric mucosal surface pH.** *Yonsei Med J*. 2012; **53(6)**:1154-1158.
4. **Risch HA**. **Pancreatic cancer: Helicobacter pylori colonization, N-nitrosamine exposures, and ABO blood group.** *Mol Carcinog*. 2012; **51(1)**: 109-118.
5. **Gawin A**, Wex T, Ławniczak M, Malfertheiner P, Starzyńska T. **Helicobacter pylori infection in pancreatic cancer.** *Pol Merkuri Lekarski*. 2012; **32(188)**: 103-107. [Article in Polish]
6. **Trikudanathan G**, Philip A, Dasanu CA, Baker WL. **Association between Helicobacter pylori infection and pancreatic cancer. A cumulative meta-analysis.** *JOP*. 2011; **12(1)**: 26-31.
7. **Nath G**, Gulati AK, Shukla VK. **Role of bacteria in carcinogenesis, with special reference to carcinoma of the gallbladder.** *World J Gastroenterol*. 2010; **16(43)**: 5395-5404.
8. **Tsuchida A**, Itoi T. **Carcinogenesis and chemoprevention of biliary tract cancer in pancreaticobiliary maljunction.** *World J Gastrointest Oncol*. 2010; **2(3)**: 130-135.
9. **Karagin PH**, Stenram U, Wadström T, Ljungh Å. **Helicobacter species and common gut bacterial DNA in gallbladder with cholecystitis.** *World J Gastroenterol*. 2010; **16(38)**: 4817-4822.
10. **Mishra RR**, Tewari M, Shukla HS. **Helicobacter species and pathogenesis of gallbladder cancer.** *Hepatobiliary Pancreat Dis Int*. 2010; **9(2)**: 129-134.
11. **Tischler AD**, McKinney JD. **Contrasting persistence strategies in Salmonella and Mycobacterium.** *Curr Opin Microbiol*. 2010; **13(1)**: 93-99.
12. **Chang AH**, Parsonnet J. **Role of bacteria in oncogenesis.** *Clinical Microbiology Reviews*. 2010; **23(4)**: 837-857.
13. **Pandey M**, Mishra RR, Dixit R, Jaiswal R, Shukla M, Nath G. **Helicobacter bilis in human gallbladder cancer: results of a case-control study and a meta-analysis.** *Asian Pac J Cancer Prev*. 2010; **11(2)**: 343-347.
14. **Kosaka T**, Tajima Y, Kuroki T, Mishima T, Adachi T, Tsuneoka N, Fukuda K, Kanematsu T. **Helico-**

Web-site: <http://www.drurumin.com>

E-mail: drjacobturumin@yahoo.com

- bacter bilis colonization of the biliary system in patients with pancreaticobiliary maljunction. *Br J Surg.* 2010; **97(4)**: 544-549.
15. Bostanoğlu E, Karahan ZC, Bostanoğlu A, Savaş B, Erden E, Kiyan M. Evaluation of the presence of *Helicobacter species* in the biliary system of Turkish patients with cholelithiasis. *Turk J Gastroenterol.* 2010; **21(4)**: 421-427.
 16. Risch HA, Yu H, Lu L, Kidd MS. ABO blood group, *Helicobacter pylori* seropositivity, and risk of pancreatic cancer: a case-control study. *J Natl Cancer Inst.* 2010; **102(7)**: 502-505.
 17. Shimoyama T, Takahashi R, Abe D, Mizuki I, Endo T, Fukuda S. Serological analysis of *Helicobacter hepaticus* infection in patients with biliary and pancreatic diseases. *J Gastroenterol Hepatol.* 2010; **25(Suppl 1)**: S86-S89.
 18. Kucheriavyi IuA. Chronic pancreatitis as acid-dependent disease. *Eksp Klin Gastroenterol.* 2010; **9**: 107-115.
 19. Pandey M, Shukla M. *Helicobacter species* are associated with possible increase in risk of hepatobiliary tract cancers. *Surg Oncol.* 2009; **18(1)**: 51-56.
 20. Hamada T, Yokota K, Ayada K, Hirai K, Kamada T, Haruma K, Chayama K, Oguma K. Detection of *Helicobacter hepaticus* in human bile samples of patients with biliary disease. *Helicobacter.* 2009; **14(6)**: 545-551.
 21. Maurer KJ, Carey MC, Fox JG. Roles of infection, inflammation, and the immune system in cholesterol gallstone formation. *Gastroenterology.* 2009; **136(2)**: 425-440.
 22. Yucebilgili K, Mehmetoğlu T, Gucin Z, Salih BA. *Helicobacter pylori* DNA in gallbladder tissue of patients with cholelithiasis and cholecystitis. *J Infect Dev Ctries.* 2009; **3(11)**: 856-859.
 23. Hamada T, Yokota K, Ayada K, Hirai K, Kamada T, Haruma K, Chayama K, Oguma K. Detection of *Helicobacter hepaticus* in human bile samples of patients with biliary disease. *Helicobacter.* 2009; **14(6)**: 545-551.
 24. Elwood DR. Cholecystitis. *Surg Clin North Am.* 2008; **88(6)**: 1241-1252.
 25. Chen DF, Hu L, Yi P, Liu WW, Fang DC, Cao H. *Helicobacter pylori* damages human gallbladder epithelial cells in vitro. *World J Gastroenterol.* 2008; **14(45)**: 6924-6928.
 26. Abu Al-Soud W, Stenram U, Ljungh A, Tranberg KG, Nilsson HO, Wadström T. DNA of *Helicobacter spp.* and common gut bacteria in primary liver carcinoma. *Dig Liver Dis.* 2008; **40(2)**: 126-131.
 27. Abeyesuriya V, Deen KI, Wijesuriya T, Salgado SS. Microbiology of gallbladder bile in uncomplicated symptomatic cholelithiasis. *Hepatobiliary Pancreat Dis Int.* 2008; **7(6)**: 633-637.
 28. Chen DF, Hu L, Yi P, Liu WW, Fang DC, Cao H. *H. pylori* exist in the gallbladder mucosa of patients with chronic cholecystitis. *World J Gastroenterol.* 2007; **13(10)**: 1608-1611.
 29. Misra V, Misra SP, Dwivedi M, Shouche Y, Dharme M, Singh PA. *Helicobacter pylori* in areas of gastric metaplasia in the gallbladder and isolation of *H. pylori* DNA from gallstones. *Pathology.* 2007; **39(4)**: 419-424.
 30. Pandey M. *Helicobacter species* are associated with possible increase in risk of biliary lithiasis and benign biliary diseases. *World J Surg Oncol.* 2007; **5(94)**: 1-5.
 31. Bohr UR, Kuester D, Meyer F, Wex T, Stillert M, Csepregi A, Lippert H, Roessner A, Malfertheiner P. Low prevalence of *Helicobacter species* in gallstone disease and gallbladder carcinoma in the German population. *Clin Microbiol Infect.* 2007; **13(5)**: 525-531.
 32. Nilsson HO, Stenram U, Ihse I, Wadstrom T. *Helicobacter species* ribosomal DNA in the pancreas, stomach and duodenum of pancreatic cancer patients. *World J Gastroenterol.* 2006; **12(19)**: 3038-3043.
 33. Maurer KJ, Rogers AB, Ge Z, Wiese AJ, Carey MC, Fox JG. *Helicobacter pylori* and cholesterol gallstone formation in C57L/J mice: a prospective study. *Am J Physiol Gastrointest Liver Physiol.* 2006; **290(1)**: G175-G182.
 34. Nilsson HO, Pietroiusti A, Gabrielli M, Zocco MA, Gasbarrini G, Gasbarrini A. *Helicobacter pylori* and extragastric diseases – other *Helicobacters*. *Helicobacter.* 2005; **10(Suppl 1)**: 54-65.
 35. Abayli B, Colakoglu S, Serin M, Erdogan S, Isiksal YF, Tuncer I, Koksall F, Demiryurek H. *Helicobacter pylori* in the etiology of cholesterol gallstones. *J Clin Gastroenterol.* 2005; **39(2)**: 134-137.
 36. Swidsinski A, Schlien P, Pernthaler A, Gottschalk U, Bärlechner E, Decker G, Swidsinski S, Strassburg J, Loening-Baucke V, Hoffmann U, Seehofer D, Hale LP, Lochs H. Bacterial biofilm within diseased pancreatic and biliary tracts. *Gut.* 2005; **54(3)**: 388-395.
 37. Maurer KJ, Ihrig MM, Rogers AB, Ng V, Bouchard G, Leonard MR, Carey MC, Fox JG. Identification of cholelithogenic enterohepatic *Helicobacter species* and their role in murine cholesterol gallstone formation. *Gastroenterology.* 2005; **128(4)**: 1023-1033.
 38. Murata H, Tsuji S, Tsujii M, Fu HY, Tanimura H, Tsujimoto M, Matsuura N, Kawano S, Hori M. *Helicobacter bilis* infection in biliary tract cancer. *Aliment Pharmacol Ther.* 2004; **20(Suppl 1)**: 90-94.
 39. Farshad Sh, Alborzi A, Malek Hosseini SA, Oboodi B, Rasouli M, Japoni A, Nasiri J. Identification of *Helicobacter pylori* DNA in Iranian patients with gallstones. *Epidemiol Infect.* 2004; **132(6)**: 1185-1189.
 40. Hazrah P, Oahn KT, Tewari M, Pandey AK, Kumar K, Mohapatra TM, Shukla HS. The frequency of live bacteria in gallstones. *HPB (Oxford).* 2004; **6(1)**: 28-32.
 41. Lu Y, Zhang BY, Shi JS, Wu LQ. Expression of the bacterial gene in gallbladder carcinoma tissue and bile. *Hepatobiliary Pancreat Dis Int.* 2004; **3(1)**: 133-135.
 42. Silva CP, Pereira-Lima JC, Oliveira AG, Guerra JB, Marques DL, Sarmanho L, Cabral MM, Queiroz DM. Association of the presence of *Helicobacter* in gallbladder tissue with cholelithiasis and cholecys-

- titis. *J Clin Microbiol.* 2003; **41(12)**: 5615-5618.
43. **Bulajic M**, Maisonneuve P, Schneider-Brachert W, Müller P, Reischl U, Stimec B, Lehn N, Lowenfels AB, Löhr M. **Helicobacter pylori and the risk of benign and malignant biliary tract disease.** *Cancer.* 2002; **95(9)**: 1946-1953.
 44. **Fukuda K**, Kuroki T, Tajima Y, Tsuneoka N, Kitajima T, Matsuzaki S, Furui J, Kanematsu T. **Comparative analysis of Helicobacter DNAs and biliary pathology in patients with and without hepatobiliary cancer.** *Carcinogenesis.* 2002; **23(11)**: 1927-1931.
 45. **Fox JG**. **The non-H pylori helicobacters: their expanding role in gastrointestinal and systemic diseases.** *Gut.* 2002; **50(2)**: 273-283.
 46. **Matsukura N**, Yokomuro S, Yamada S, Tajiri T, Sundo T, Hadama T, Kamiya S, Naito Z, Fox JG. **Association between Helicobacter bilis in bile and biliary tract malignancies: H. bilis in bile from Japanese and Thai patients with benign and malignant diseases in the biliary tract.** *Jpn J Cancer Res.* 2002; **93(7)**: 842-847.
 47. **Monstein HJ**, Jonsson Y, Zdolsek J, Svanvik J. **Identification of Helicobacter pylori DNA in human cholesterol gallstones.** *Scand J Gastroenterol.* 2002; **37(1)**: 112-119.
 48. **Nilsson HO**, Mulchandani R, Tranberg KG, Stenram U, Wadström T. **Helicobacter species identified in liver from patients with cholangiocarcinoma and hepatocellular carcinoma.** *Gastroenterology.* 2001; **120(1)**: 323-324.
 49. **Harada K**, Ozaki S, Kono N, Tsuneyama K, Katayanagi K, Hiramatsu K, Nakanuma Y. **Frequent molecular identification of Campylobacter but not Helicobacter genus in bile and biliary epithelium in hepatolithiasis.** *J Pathol.* 2001; **193(2)**: 218-223.
 50. **Myung SJ**, Kim MH, Shim KN, Kim YS, Kim EO, Kim HJ, Park ET, Yoo KS, Lim BC, Seo DW, Lee SK, Min YI, Kim JY. **Detection of Helicobacter pylori DNA in human biliary tree and its association with hepatolithiasis.** *Dig Dis Sci.* 2000; **45(7)**: 1405-1412.
 51. **Fox JG**, Dewhirst FE, Shen Z, Feng Y, Taylor NS, Paster BJ, Ericson RL, Lau CN, Correa P, Araya JC, Roa I. **Hepatic Helicobacter species identified in bile and gallbladder tissue from Chileans with chronic cholecystitis.** *Gastroenterology.* 1998; **114(4)**: 755-763.
 52. **Kawaguchi M**, Saito T, Ohno H, Midorikawa S, Sanji T, Handa Y, Morita S, Yoshida H, Tsurui M, Misaka R, Hirota T, Saito M, Minami K. **Bacteria closely resembling Helicobacter pylori detected immunohistologically and genetically in resected gallbladder mucosa.** *J Gastroenterol.* 1996; **31(2)**: 294-298.
 53. **Gonzalez-Escobedo G**, Gunn JS. **Identification of Salmonella enterica Serovar Typhimurium Genes Regulated during Biofilm Formation on Cholesterol Gallstone Surfaces.** *Infect Immun.* 2013; **81(10)**: 3770-3780.
 54. **Gonzalez-Escobedo G**, Gunn JS. **Gallbladder epithelium as a niche for chronic Salmonella carriage.** *Infect Immun.* 2013; **81(8)**: 2920-2930.
 55. **Charles RC**, Sultana T, Alam MM, Yu Y, Wu-Freeman Y, Bufano MK, Rollins SM, Tsai L, Harris JB, Larocque RC, Leung DT, Brooks WA, Nga TV, Dongol S, Basnyat B, Calderwood SB, Farrar J, Khanam F, Gunn JS, Qadri F, Baker S, Ryan ET. **Identification of Immunogenic Salmonella enterica Sero-type Typhi Antigens Expressed in Chronic Biliary Carriers of S. Typhi in Kathmandu, Nepal.** *PLoS Negl Trop Dis.* 2013; **7(8)**: e2335.
 56. **Safaeian M**, Gao YT, Sakoda LC, Quraishi SM, Rashid A, Wang BS, Chen J, Pruckler J, Mintz E, Hsing AW. **Chronic typhoid infection and the risk of biliary tract cancer and stones in Shanghai, China.** *Infect Agent Cancer.* 2011; **6(6)**: 1-3.
 57. **Gonzalez-Escobedo G**, Marshall JM, Gunn JS. **Chronic and acute infection of the gallbladder by Salmonella Typhi: understanding the carrier state.** *Nat Rev Microbiol.* 2011; **9(1)**: 9-14.
 58. **Ahmer BM**, Gunn JS. **Interaction of Salmonella spp. with the Intestinal Microbiota.** *Front Microbiol.* 2011; **2(101)**: .
 59. **Gunn JS**. **Salmonella host-pathogen interactions: a special topic.** *Front Microbiol.* 2011; **2(191)**: 1-2.
 60. **Knodler LA**, Vallance BA, Celli J, Winfree S, Hansen B, Montero M, Steele-Mortimer O. **Dissemination of invasive Salmonella via bacterial-induced extrusion of mucosal epithelia.** *Proc Natl Acad Sci USA.* 2010; **107(41)**: 17733-17738.
 61. **Crawford RW**, Rosales-Reyes R, Ramírez-Aguilar Mde L, Chapa-Azuela O, Alpuche-Aranda C, Gunn JS. **Gallstones play a significant role in Salmonella spp. gallbladder colonization and carriage.** *Proc Natl Acad Sci USA.* 2010; **107(9)**: 4353-4358.
 62. **Crawford RW**, Reeve KE, Gunn JS. **Flagellated but not hyperfimbriated Salmonella enterica serovar Typhimurium attaches to and forms biofilms on cholesterol-coated surfaces.** *J Bacteriol.* 2010; **192(12)**: 2981-2990.
 63. **Crawford RW**, Gibson DL, Kay WW, Gunn JS. **Identification of a bile-induced exopolysaccharide required for Salmonella biofilm formation on gallstone surfaces.** *Infect Immun.* 2008; **76(11)**: 5341-5349.
 64. **Prouty AM**, Gunn JS. **Comparative analysis of Salmonella enterica serovar Typhimurium biofilm formation on gallstones and on glass.** *Infect Immun.* 2003; **71(12)**: 7154-7158.
 65. **Prouty AM**, Schwesinger WH, Gunn JS. **Biofilm formation and interaction with the surfaces of gallstones by Salmonella spp.** *Infect Immun.* 2002; **70(5)**: 2640-2649.
 66. **Dutta U**, Garg PK, Kumar R, Tandon RK. **Typhoid carriers among patients with gallstones are at increased risk for carcinoma of the gallbladder.** *Am J Gastroenterol.* 2000; **95(3)**: 784-787.